

# Treatment of *Pseudomonas* Keratitis by Continuous Infusion of Topical Antibiotics With the Morgan Lens

Mingwu Wang, MD, PhD,\*† Whitney A. Smith, MD,‡ Joshua K. Duncan, DO,§ and Joseph M. Miller, MD, MPH†

**Purpose:** Despite following standard treatment, *Pseudomonas* keratitis can continue to progress and result in loss of vision or of the eye. Our cases demonstrate that the Morgan Lens can be an effective topical antibiotic delivery vehicle in advanced keratitis.

**Methods:** Two patients (3 eyes) with *Pseudomonas* keratitis were included in this report after failing to respond to intense inpatient topical treatment. Because loss of the eyes was imminent, the Morgan Lenses were used for continuous lavage with ceftazidime (50 mg/mL), in conjunction with other conventional treatment.

**Results:** Three days after lavage, corneal cultures became negative in all eyes. Infusion was continued for at least a week to ensure sterilization of the infection before switching to standard topical therapy. The infection in both cases was promptly eradicated and the eyes were rescued.

**Conclusions:** The Morgan Lens can be a viable alternative in treating severe and aggressive infectious keratitis or sclerokeratitis. Application of the Morgan Lens is noninvasive and requires minimal training. Intravenous tubing connectors allow for easy swapping between medications, simultaneous administration of multiple medications, and titration of dosing. Additionally, it is cost-effective as the low demand for nursing care essentially eliminates the need for intensive care unit admission.

**Key Words:** *Pseudomonas aeruginosa* keratitis, Morgan Lens, antibiotic lavage

(*Cornea* 2017;36:617–620)

*Pseudomonas aeruginosa* is a gram-negative rod typically found in soil and water, commonly implicated in healthcare-associated infections, particularly in critically ill

or immunocompromised patients. It is responsible for 6% to 39% of bacterial keratitis cases in the United States.<sup>1</sup> The prevalence and severity of the disease are on the rise due in part to the increasing drug resistance in *P. aeruginosa* keratitis isolates.<sup>2</sup> The infection occurs after a break in the corneal epithelium. Risk is dramatically increased in those who regularly wear contact lens, especially in patients who sleep wearing their lenses. *P. aeruginosa* is also highly virulent, and its infection is generally aggressive, destructive, and difficult to treat.<sup>3</sup>

Standard treatment consists of topical fluoroquinolones, cephalosporins, or aminoglycosides used frequently (every 1–2 hours) around the clock.<sup>4</sup> However, some *Pseudomonas* ulcers can continue to progress and result in permanent loss of vision or of the affected eye. Therefore, achieving timely containment of *Pseudomonas* infection is vitally important. Subpalpebral antibiotic lavage treatment is reportedly effective for severe and refractory scleritis and keratitis.<sup>5</sup> However, placement of the subpalpebral lavage catheter requires training and may inevitably result in permanent lid scarring and palpebral levator aponeurosis dysfunction.

The Morgan Lens (MorTan, Inc, Missoula, MT) was originally designed as a device for continuous drug delivery to the eye for ocular lavage<sup>6</sup> but contemporarily is mainly used as an irrigation device in the emergency department after chemical exposure. We have recently used the Morgan Lens for continuous infusion of antibiotics in several aggressive cases of *Pseudomonas* keratitis and achieved timely clinical sterility of the cornea. In this study, we report our experience in treating 2 of these severe cases.

## MATERIALS AND METHODS

Two patients (3 eyes) were included in this report. Despite following standard treatment, *Pseudomonas* keratitis continued to progress and threatened the affected eyes. Rapid containment of the infection was imperative.

### Case 1

An 11-year-old healthy girl presented with an ulcer in the right eye after swimming wearing her contact lenses. The ulcer was located at the superotemporal cornea involving the visual axis, and vision at presentation was 20/100. The patient was admitted to the Pediatric Intensive Care Unit (PICU) and

Received for publication September 22, 2016; revision received November 13, 2016; accepted November 16, 2016. Published online ahead of print December 20, 2016.

From the \*NeuVision Medical Institute, Tucson, AZ; †Department of Ophthalmology and Visual Science, College of Medicine, University of Arizona, Tucson, AZ; ‡Updegraff Laser Vision, St Petersburg, FL; and §Department of Ophthalmology, Baylor College of Medicine, Houston, TX. The authors have no funding or conflicts of interest to disclose.

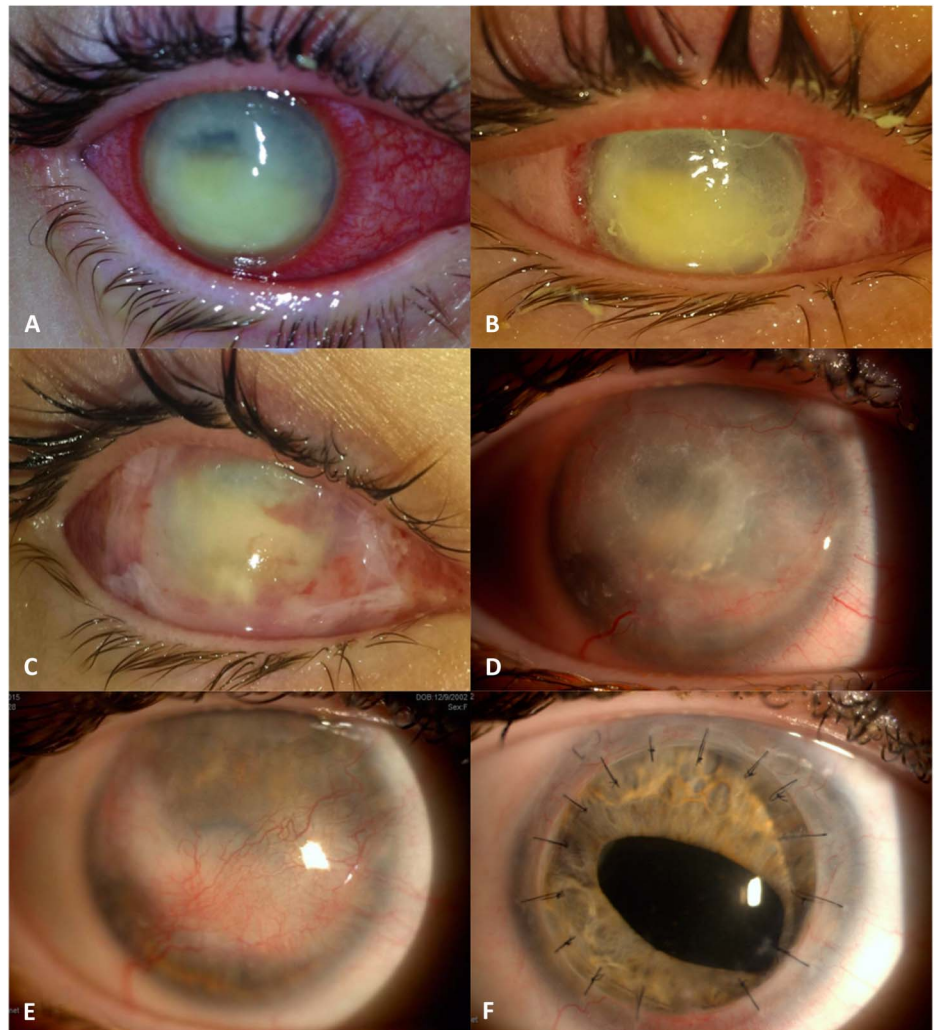
Reprints: Mingwu Wang, MD, PhD, Cornea Associates, 6422 E. Speedway Boulevard, Suite 100, Tucson, AZ 85710 (e-mail: mingwuwang@hotmail.com).

Copyright © 2016 Wolters Kluwer Health, Inc. All rights reserved.

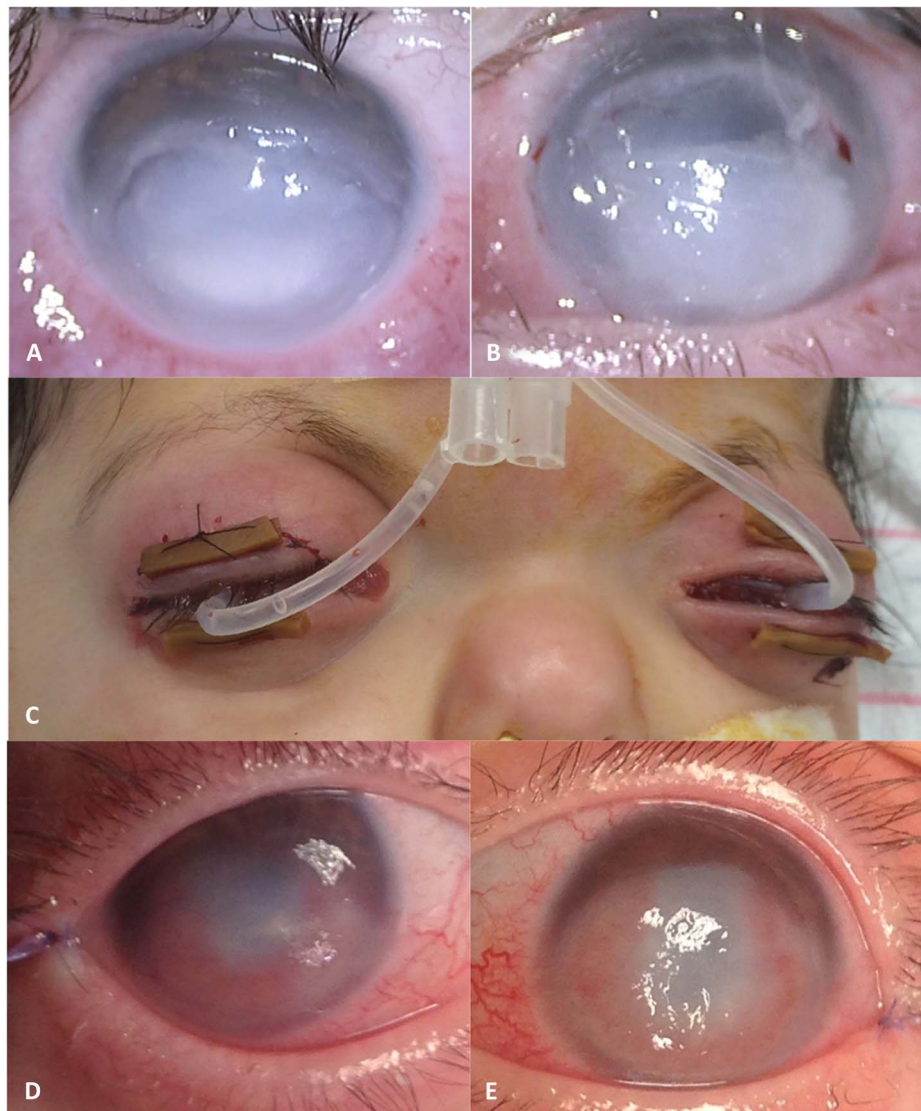
was administered 50 mg/mL vancomycin and 14 mg/mL tobramycin alternating every 1 hour in the right eye. Corneal scrape culture was positive for *P. aeruginosa*, highly sensitive to antibiotics including ciprofloxacin and tobramycin. Within 3 days, the patient reported improvement in eye pain and photosensitivity, and the initial hypopyon resolved. The patient was discharged home with the prescription of 14 mg/mL tobramycin every 1 hour and ciprofloxacin 4 times a day while awake and was followed every 2 to 3 days. One week later, while still on the same regimen, hypopyon reappeared and the ulcer worsened. The patient was readmitted, and the ulcer was scraped again for culture. The original inpatient regimen was resumed, and 0.15% amphotericin B every 2 hours, 0.1% desomedine every 2 hours, and oral fluconazole 200 mg daily were added, considering the possibility of concomitant fungal or *Acanthamoeba* infections. Within 48 hours, Gram and Giemsa stains showed no fungal or *Acanthamoeba* elements, and the culture and sensitivity results were essentially unchanged. Meanwhile, the ulcer continued to become deeper and larger, hypopyon reached to about 60%, and corneal perforation appeared imminent (Fig. 1A).

A literature search disclosed the subpalpebral antibiotic lavage therapy as an alternative for failed topical treatment of severe keratitis.<sup>5</sup> As it is an invasive procedure associated with undesirable lid scarring and possible lid levator dysfunction, the Morgan Lens was considered instead. Continuous infusion of ceftazidime 50 mg/mL at 20 mL/h was delivered through the Morgan Lens and an electronic intravenous (IV) pump. Every hour, ceftazidime infusion was temporarily stopped for 10 minutes and 5 mL of either 0.15% amphotericin B or 0.1% Desomedine was pushed through a syringe into the tubing of the Morgan Lens so that each medication was given every 2 hours, respectively. Oral fluconazole was continued while more culture results were pending. Mild conscious sedation was given intermittently to improve the comfort of the infected eye. Daily examination of the eye was possible by temporarily extracting the Morgan Lens. On day 2 of infusion, the patient reported increasing pain. The cornea was covered with loose necrotic debris although the hypopyon appeared the same. Severe inflammation of the conjunctiva with membranous exudate was noted and the paralimbal sclera was more injected (Fig. 1B). To evaluate the possibility of evolving scleritis, the patient

**FIGURE 1.** Slit-lamp photographs of the right eye. A, Worsening of keratitis under standard topical treatment with thinning of the cornea and hypopyon of about 60%. B, Two days after infusion, severe inflammation of the conjunctiva with membranous exudate was noted. The paralimbal sclera was more injected. C, Five days after continuous lavage, 2 microscopic perforations were repaired with glue and amniotic membrane overlays. The exudative conjunctival inflammation appeared to have improved. D, One month after discontinuation of Morgan Lens lavage, the corneal ulcer had healed completely with extensive scarring and neovascularization. E, Four months later, the keratitis became quiescent with dense neovascular corneal scars in the areas of previous perforation. White cataract developed with discernable posterior synechiae of the iris to the lens. F, Three months after undergoing penetrating keratoplasty with cataract extraction and intraocular lens placement, the patient achieved best spectacle-corrected visual acuity of 20/40.







**FIGURE 2.** A and B, After 2 days of standard topical treatment, extensive ulceration with corneal thinning was noted, more in the left eye than in the right eye. C, Bilateral temporary tarsorrhaphies were placed to secure the Morgan Lenses for continuous lavage. D and E, The infections were eradicated 1 month after initiation of continuous lavage through the Morgan Lens. Significant bilateral corneal scarring with neovascularization occurred.

was examined under anesthesia (EUA). Corneal biopsies and scrapings at the edge of the ulcer were taken for more cultures and special stains, specifically to rule out fungal and *Acanthamoeba* infections. Two microscopic corneal perforations were glued and patched with amniotic membrane overlays. After finding no evidence of necrotizing scleritis, continuous lavage of 25 mg/mL ceftazidime was resumed. Repeated cultures remained negative and special stains revealed no fungi or *Acanthamoeba* in corneal biopsies. All antifungal and *Acanthamoeba* medications were immediately discontinued, and topical 1% prednisolone twice a day was started. On day 5, another microscopic perforation was noted and repaired. Exudative conjunctival inflammation appeared improved (Fig. 1C). A total of 7 days of continuous ceftazidime lavage had been given before switching to topical medications and the dosing was adjusted accordingly. One month after discontinuation of the Morgan Lens lavage, the cornea ulcer had healed completely with extensive scarring and neovascularization (Fig. 1D). After 4 months, keratitis

became quiescent with dense neovascular scars in the areas of previous perforation. The patient had white cataract develop with discernable posterior synechiae of the iris to the lens (Fig. 1E) and vision of light perception. Six months after initial presentation, the patient underwent penetrating keratoplasty with cataract extraction and intraocular lens placement. Three months after surgery, the patient achieved best spectacle-corrected vision of 20/40 (Fig. 1F).

## Case 2

An 11-month old girl with Apert syndrome was admitted for complicated pneumonia and required intubation for respiratory distress. Bilateral shallow orbits led to lagophthalmos and corneal exposure. The PICU nurses noted corneal opacities and took a swab of purulent discharge for culture. After ophthalmological consultation, 50 mg/mL vancomycin and 14 mg/mL tobramycin every 1 hour were administered in both eyes topically. The swab specimen

showed Gram-negative rods. With 2 days of treatment, the ulcers continued to progress and the patient was taken for EUA. Extensive ulceration with corneal thinning was noted in both eyes (Fig. 2A, B). Cultures from both eyes were positive for *P. aeruginosa*. To quickly contain the infection, bilateral continuous infusion through the Morgan Lenses was initiated with ceftazidime, 50 mg/mL at 20 mL/h. Temporary tarsorrhaphies were placed to secure the lenses in place (Fig. 2C). Three days later, another EUA was performed and the infections showed no signs of progression. Cultures from this time point onward remained negative. Continuous lavage was resumed for 4 more days, and permanent lateral tarsorrhaphies were performed. A tapered course of topical fortified ceftazidime was then followed up for 1 month along with ciprofloxacin ointment. Significant bilateral corneal scarring with neovascularization occurred (Fig. 2D, E). She is scheduled to undergo penetrating keratoplasty after corrective craniofacial operations.

## DISCUSSION

Microbial keratitis is a leading cause of corneal blindness. Severe *Pseudomonas* keratitis can result in corneal scarring, irregular astigmatism, and permanent visual loss. Prompt surgical management, such as lamellar and penetrating corneoscleral grafts, has been suggested for refractory keratoscleritis,<sup>7</sup> but these grafts have high risk of rejection and failure. The aggressive nature of *Pseudomonas* keratitis combined with evolving multidrug resistance has led to an increase in ocular morbidity.<sup>8</sup> Upon topical application, each drop is diluted by reflex tearing and dispersed by blinking, and only 1% to 7% of drug is absorbed.<sup>9</sup> Therefore, effective therapeutic concentration is only achieved transiently at the ocular surface. Alternative delivery methods that can maintain long-lasting therapeutic concentration are especially needed in progressive and refractory infections. Meallet<sup>5</sup> demonstrated successful treatment of 6 patients with severe infectious scleritis and keratitis using subpalpebral lavage of topical antibiotics. This procedure involves passing an IV tube into the superior fornix through the upper lid, which requires training and can cause permanent eyelid scarring and dysfunction. Topical medications combined with corneal intrastromal and subconjunctival injection of antibiotics have also been commonly applied clinically with variable results.

In this case series, we demonstrated the efficacy in eradication of rapidly progressing *Pseudomonas* keratitis using the Morgan Lens. Use of this lens can achieve high antibiotic concentration rapidly in ocular surface tissues.<sup>10</sup> Precise titration of the medications is possible through the IV pump. Placement of the lens requires no or minimal training and is noninvasive and generally well tolerated. The lens can

be easily removed to allow for clinical monitoring of therapeutic effects. Although hospitalization may still be necessary, the reduced demand for nursing care no longer requires ICU admission.

Interestingly, the originally proposed use of the Morgan Lens included a vehicle for antibiotic delivery for the treatment of infectious keratitis.<sup>6</sup> Since then, the Morgan Lens has been tested in animal experiments,<sup>10</sup> and applied in humans in Ghana<sup>11</sup> and Italy.<sup>12</sup> However, such an application has hardly been adopted by ophthalmologists worldwide. In the 2006 article by Meallet,<sup>5</sup> use of the Morgan Lens as an alternative was not mentioned. Continuous lavage with antibiotics using the Morgan Lens has been shown to be more effective than topical therapy in animal models and was able to achieve higher concentrations in the aqueous humor when compared with drops administered every 15 to 30 minutes.<sup>10</sup> Applying drops at this frequency, or even hourly, is difficult for patients, and if admitted, often requires ICU-level nursing care with drastically increased cost. Human studies have shown that the use of the Morgan Lens is safe for up to 15 days.<sup>11,12</sup> Because of its ease of use, efficacy, ready availability, and increased patient compliance, we strongly believe that continuous antibiotic infusion through the Morgan Lens should be considered a viable alternative therapy for refractory or fulminant corneal infections.

## REFERENCES

1. Varaprasathan G, Miller K, Lietman T, et al. Trends in the etiology of infectious corneal ulcers at the F. I. Proctor Foundation. *Cornea*. 2004; 23:360–364.
2. Garg P, Sharma S, Rao GN. Ciprofloxacin-resistant *Pseudomonas* keratitis. *Ophthalmology*. 1999;106:1319–1323.
3. Sy A, Srinivasan M, Mascarenhas J, et al. *Pseudomonas aeruginosa* keratitis: outcomes and response to corticosteroid treatment. *Invest Ophthalmol Vis Sci*. 2012;53:267–272.
4. Chawla B, Agarwal P, Tandon R, et al. In vitro susceptibility of bacterial keratitis isolates to fourth-generation fluoroquinolones. *Eur J Ophthalmol*. 2010;20:300–305.
5. Meallet MA. Subpalpebral lavage antibiotic treatment for severe infectious scleritis and keratitis. *Cornea*. 2006;25:159–163.
6. Morgan LB. A new drug delivery system for the eye. *IMS Ind Med Surg*. 1971;40:11–13.
7. Reynolds MG, Alfonso E. Treatment of infectious scleritis and keratoscleritis. *Am J Ophthalmol*. 1991;112:543–547.
8. Vazirani J, Wurity S, Ali MH. Multidrug-resistant *Pseudomonas aeruginosa* keratitis: risk factors, clinical characteristics, and outcomes. *Ophthalmology*. 2015;122:2110–2114.
9. Järvinen KJT, Urtti A. Ocular absorption following topical delivery. *Adv Drug Deliv Rev*. 1996;16:3–19.
10. Rootman DS, Krajden M. Continuous flow perfusion of gentamicin with a scleral shell reduces bacterial colony counts in experimental *Pseudomonas* keratitis. *J Ocul Pharmacol*. 1993;9:271–276.
11. Oppong M. Experience with Morgan perfusion contact lens in treating eye infections and burns. *Ghana Med J*. 1975;14:201–205.
12. Bellucci R. Morgan lens safe and effective for long-term use in corneal infections. *Ocular Surgery News*. 2002.